

Effective Management of Venous Leg Ulcers by Copper Dressings – Case Series

Sergii Karpeniuk ¹, Laura Baltà-Domínguez ², Sofia Megino-Escobar ², Rubén Molina-Carrillo ², Eduardo González Álvarez ², Katia Furtado ^{3,4}, Paulo Ramos ⁵, Amanda M. Fuller ⁶, Cernica Chausha Weitman ⁷, Ingrida Ašakienė ⁸, Kinga Spyrka ⁹, Tohar Roth ¹⁰, and Gadi Borkow ^{10*}

¹Department of Surgery No.1, Urology, Minimally Invasive Surgery, I. Horbachevsky Ternopil National Medical University, 46011 Ternopil, Ukraine.

²Enfermeras Expertas en Herides Complejas. Atenció Primària Barcelona Ciutat, Institut Català de la Salut; 08036 Barcelona, Spain.

³Outpatient Department, Hospital of Portalegre, Unidade Local de Saúde Alto Alentejo, 7300-312 Portalegre, Portugal.

⁴Comprehensive Health Research Centre (CHRC), Universidade de Évora, 7000-671 Évora, Portugal.

⁵Unidade Local de Saúde, Póvoa de Varzim Vila do Conde, 4480-701 Vila do Conde, Portugal.

⁶Hocking Valley Community Hospital, Outpatient Wound Clinic, 43138 Ohio, USA.

⁷Hadassah Medical Center, 91120 Jerusalem, Israel.

⁸Vilnius University Hospital Santaros, 08661 Klinikos, Lithuania.

⁹Wladyslaw Bieganski Collegium Medicum, Jan Długosz University in Częstochowa, 42-200 Częstochowa, Poland.

¹⁰MedCu Technologies Ltd., 4672200 Herzliya, Israel.

***Corresponding Author:** Gadi Borkow, MedCu Technologies Ltd., 4672200 Herzliya, Israel.

Received Date: October 15, 2025 | **Accepted Date:** October 29, 2025 | **Published Date:** October 31, 2025

Citation: Sergii Karpeniuk, Laura B. Domínguez, Sofia M. Escobar, Rubén M. Carrillo, Eduardo G. Álvarez, et al, (2025), Effective Management of Venous Leg Ulcers by Copper Dressings – Case Series, *International Journal of Clinical Case Reports and Reviews*, 31(1); DOI:10.31579/2690-4861/986

Copyright: © 2025, Gadi Borkow. This is an open-access article distributed under the terms of the Creative Commons Attribution License, which permits unrestricted use, distribution, and reproduction in any medium, provided the original author and source are credited.

Abstract:

Background/Objective: Venous leg ulcers (VLUs) remain a therapeutic challenge, particularly in patients with multiple comorbidities and poor response to standard care. This case series evaluated the use of copper oxide-impregnated wound dressings (Copper Dressings) in 25 patients with chronic, hard-to-heal VLUs.

Methods: Patients' VLUs were treated with Copper Dressings without adjunctive antimicrobials. The patients, treated across diverse geographies by different wound care specialists, included individuals with complex profiles such as chronic venous insufficiency, lymphedema, malnutrition, diabetes, rheumatoid arthritis, and wound infections.

Results: Treatment resulted in consistent clinical improvement, including enhanced autolytic debridement, granulation tissue formation, epithelialization, and reduction of periwound edema and exudate. The mean RESVECH 2.0 score improved from 19.52±5.38 at baseline to 2.44±4.92 (p<0.001). After an average of 9.6±5.87 weeks of treatment, 20 of 25 wounds (80%) fully healed. Importantly, infections, including those with antibiotic-resistant pathogens, were controlled without systemic antibiotics.

Conclusions: These findings clearly support Copper Dressings as a safe, effective, and biologically active option for managing refractory VLUs.

Key words: case series; copper oxide; dressings; venous ulcers; wound healing; antimicrobial

Introduction

Venous leg ulcers (VLUs) are a subtype of chronic wounds resulting from chronic venous insufficiency, characterized by poor blood return from the legs to the heart, which leads to pooling, increased pressure in the veins, and eventually, skin breakdown. VLUs significantly impair patients' quality of life due to pain, limited mobility, and increased risk of infection. The prevalence of VLUs varies across studies is generally reported between 1% and 3% in the adult population in developed countries [1-3]. This prevalence increases significantly in individuals over 65 years old, due to age-related changes in vascular health [3]. These ulcers account for up to 85% of lower extremity ulcers, contributing to a high burden on healthcare systems [4]. The incidence of VLUs increases with risk factors such as obesity, prolonged standing, and previous leg injuries. They are associated with a high recurrence rate and require long-term, intensive treatment [5,6]. Key clinical features include a shallow wound with irregular edges, pain, and an inflamed peri wound area with lipodermatosclerosis [7-10]. VLUs, as many other chronic wounds, may become infected [11]. Wound infections result in wound deterioration and delay wound healing. VLUs also often develop biofilms [12,13]. It has been demonstrated that less than 40% reduction in the size of a VLU (as well as diabetic foot ulcers) during first 4 weeks of wound management indicates that the wound is refractory to the ongoing treatment [14-16]. An estimated 93% of VLUs heal within 12 months, while the remaining 7% may persist unhealed for up to five years [17]. Copper oxide impregnated wound dressings, hereafter referred to as "Copper Dressings", are in clinical use since 2019 in the USA, Europe and other countries. They are cleared for the management of acute and chronic wounds, such as diabetic ulcers, pressure sores and venous ulcers, either infected or not infected wounds, by the regulatory bodies. The Copper Dressings have potent antimicrobial efficacy, both *in vitro* [18] and *in vivo*, [19,20] including against bacteria protected by biofilm [21]. Clinical studies have demonstrated the capacity of the Copper Dressings to

stimulate wound healing [22], including of hard-to-heal infected and non-infected chronic wounds that did not respond favorably to other wound management interventions [19,20,23,26]. Most of these studies were conducted with diabetic wounds and one case was reported for the successful management of a heavily infected venous ulcer by the Copper Dressings [19]. Treatment of diabetic wounds using Copper Dressings was found to be statistically significantly non-inferior to negative pressure wound therapy (NPWT) [27]. In the current case series, our aim was to examine if the Copper Dressings can also be an effective and simple management "tool" for the treatment of venous leg ulcers. To test our hypothesis, we compiled a variety of cases of stagnant, hard-to-heal VLUs that did not heal despite prior standard-of-care wound management strategies, some for even several years. We included patients with diverse underlying etiologies from different geographic locations, which were treated by different wound care experts. We report 25 cases of the successful management of VLUs by the Copper Dressings, all of which failed to heal by other wound management interventions.

Case Presentations

Copper dressings (Figure 1) are sterile, soft, single use, wound dressings composed of an internal absorbent layer for exuding wounds containing copper-oxide particles and one external non-adherent layer impregnated with copper-oxide particles. The external layer covers the internal layer from one side, is intended to be in direct contact with the wound bed and it allows the passage of the wound exudate to the absorbent layer. The wound dressings can vertically absorb ~10 times their own weight [18]. The dressings were secured to the wound site with a secondary dressing. In highly exuding wounds, the dressings were replaced every two to three days, and as the wounds dried up, the dressings were replaced less frequently (four to six days). The dressings were used to treat the VLUs in conjunction with compression therapy.

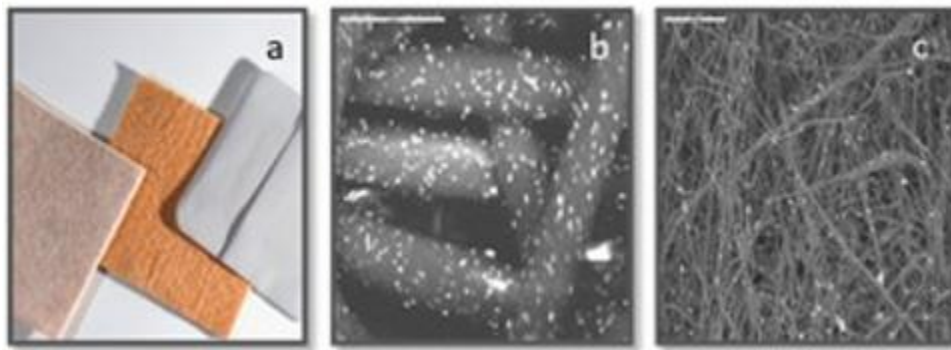


Figure 1: Copper oxide impregnated wound dressings (Copper Dressing).

(a) The dressings are composed of one or two external non-adherent orange-colored layers and a highly absorbent layer that can absorb ~10 times its own weight [18]. The dressings are provided with or without an adhesive contour. The dressings without an adhesive contour require securing by a secondary dressing. The cuprous oxide impregnated microparticles are the white dots seen in the scanning electron microscopy images of the orange layer (b) and the internal absorbent layer (c). Figure republished from [21] following permission by the authors.

Wound assessment included measurements, photographic documentation, and evaluation of healing progression, which was quantified using the RESVECH 2.0 score scale [28-30]. The RESVECH 2.0 scale is a validated wound assessment tool that provides a structured, quantitative description of chronic wounds, focusing on the following 6 dimensions: Wound Size / Area (evaluates surface area and reduction over time, with smaller area or progressive reduction = better score); Depth / Affected Tissue (describes how deep the wound extends, Superficial → dermis only; Medium → subcutaneous; Deep → muscle, tendon, or bone involved); Wound Edges (assess condition: attached, detached, undermined, macerated, necrotic, or rolled - healthy, attached edges score better); Type of Tissue in Wound Bed (proportion of necrotic, sloughy

(fibrin), granulation, and epithelial tissue - higher presence of granulation/epithelium = better score); Exudate (amount and type - serous, purulent, sanguineous- minimal or serous exudate indicates progress, heavy or purulent exudate worsens score); and Infection/Inflammation Signs (redness, warmth, swelling, pain, odor, pus - absence of infection = best score). The scale is between 35 (worst condition) to 0 (closed and healed wound) [28-30]. For each wound, the change in RESVECH 2.0 score from the beginning to the end of the copper dressing treatment (Δ score) was calculated. Since the RESVECH 2.0 scores are ordinal numbers, the Wilcoxon signed-rank test was conducted to determine if the reduction in the RESVECH 2.0 score after treatment was statistically significant. Since the use of the Copper Dressings are cleared by the relevant regulatory bodies for clinical use and are part of the standard of care, there was no need for ethical committee approvals for this retrospective study. Informed consent was obtained from all subjects involved in the study.

Results

25 patients, aged between 48 and 94 years, with a range of comorbidities—including chronic venous insufficiency, lymphedema,

hypertension, arthritis, type 2 diabetes mellitus, chronic kidney disease, or anemia (Table 1) - were treated with copper dressings for VLU that had persisted for 3 to 120 months. In all the patients' countries, the use of the copper dressings is cleared to manage VLUs and any other chronic infected and non-infected chronic wounds. All patients had previously

undergone unsuccessful wound management interventions, including compression therapy, enzymatic debridement, various topical dressings (primarily silver- and iodine-based), NPWT, and/or skin grafting (Table 1).

# Patient	Main comorbidities	Age	Gender	Presence of wounds (months)	Previous dressings	Signs of infected wound	Other
1	Severe lymphedema, anemia, calf pump dysfunction, chronic venous insufficiency	69	F	120	Gauze, Iodine dressings	Yes	-
2	Chronic venous insufficiency	65	M	60	Silver and Iodine dressings	Yes	Exposed bone
3	Chronic venous insufficiency, post-thrombotic syndrome, lymphedema, dermatitis, eczema,	48	M	60	Gauze, Iodine dressings	Yes	-
4	Chronic venous insufficiency, atherosclerosis, hypertension	70	F	48	Silver, Manuka honey and Iodine dressings	Yes	Exposed Achilles tendon
5	Heart disease, hyperlipidemia, deep veins thrombosis	82	F	40	Aguacel Ag Plus Extra	Yes	-
6	Chronic venous insufficiency, arthritis, peripheral vascular disease, celiac, hypertension, hyponatremia	72	F	39	Skin graft, simple dressings	Yes	-
7	Chronic venous insufficiency, peripheral vascular disease, hypothyroidism	68	M	36	Iodine dressings, Hydroclean, Aguacel Ag	Yes	-
8	Chronic venous insufficiency, hypothyroidism, obesity, sarcopenia, depression	53	F	24	Silver dressings	Yes	-
9	Chronic venous insufficiency, psoriasis, rheumatoid arthritis	61	F	13	Silver dressings	Yes	Exposed Achilles tendon
10	Type 2 diabetes mellitus, neuropathy, hyperlipidemia, hypertensive heart disease, dermatitis	81	M	8	Aguacel Ag, Silver foam	Yes	-
11	Chronic venous insufficiency, chronic lymphedema, hypertension,	77	F	7	NPWT, simple dressings	Yes	-

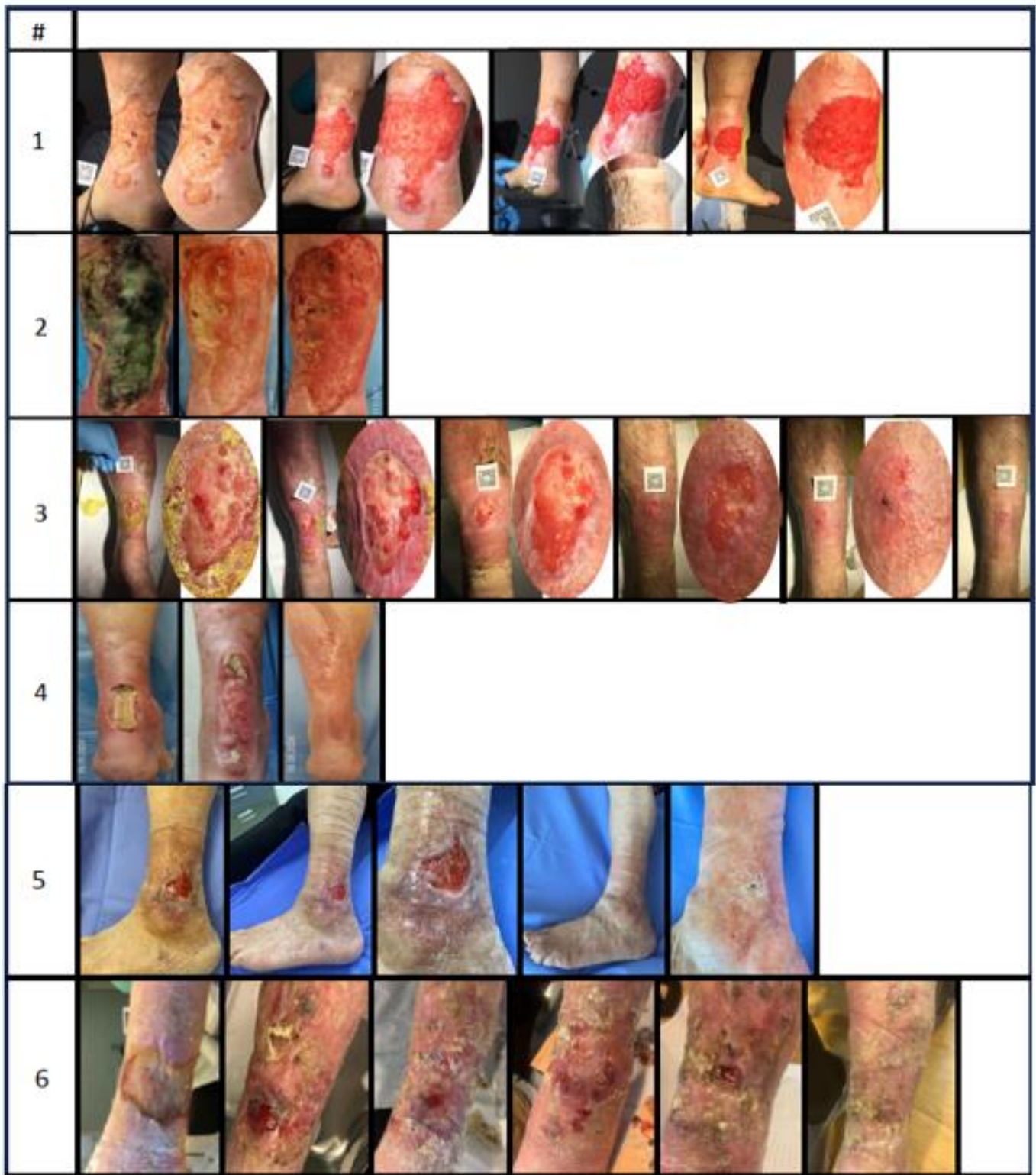
	osteoarthritis, hyperlipidemia, type 2 diabetes mellitus						
12	Chronic venous insufficiency, type 2 diabetes mellitus, bladder neoplasia, hepatic steatosis, post-thrombotic syndrome, podermatosclerosis, dermatitis	67	M	6.5	Aguacel Ag, Acticoat, Iodine dressings	Yes	-
13	Chronic venous insufficiency, type 2 diabetes mellitus, hypertensive heart disease, mixed hyperlipidemia, dermatitis, anemia	56	M	6	Aguacel Ag Plus Extra, Granuflex	Yes	-
14	Chronic venous insufficiency, chronic hepatitis C, ischemic heart disease	65	F	6	Iodine dressings, Acticoat	Yes	-
15	Chronic venous insufficiency, type 2 diabetes mellitus, hypertension, peripheral artery disease, inflammatory bowel disease, deep vein thrombosis	94	M	6	Iodine dressings, Acticoat, Aguacel Ag	Yes	Exposed bone
16	Chronic venous insufficiency, chronic osteoarticular, frailty, anemia, sarcopenia,	86	F	5	Aguacel Ag	Yes	Significant inflammation
17	Chronic venous insufficiency, type 2 diabetes mellitus, diabetic polyneuropathy, hypertension, anemia, saphenectomy, varicectomy	79	M	5	Iodine dressings	Yes	-
18	Chronic venous insufficiency, hypertension, subclinical hypothyroidism, colon neoplasia	85	F	5	Iodine dressings, Aguacel Ag	Yes	-
19	Chronic venous insufficiency, hyperlipidemia, hyperlipoproteinemia, dyslipidemia, hypertension, stasis dermatitis, cellulitis	74	M	4	Aguacel Ag	Yes	-

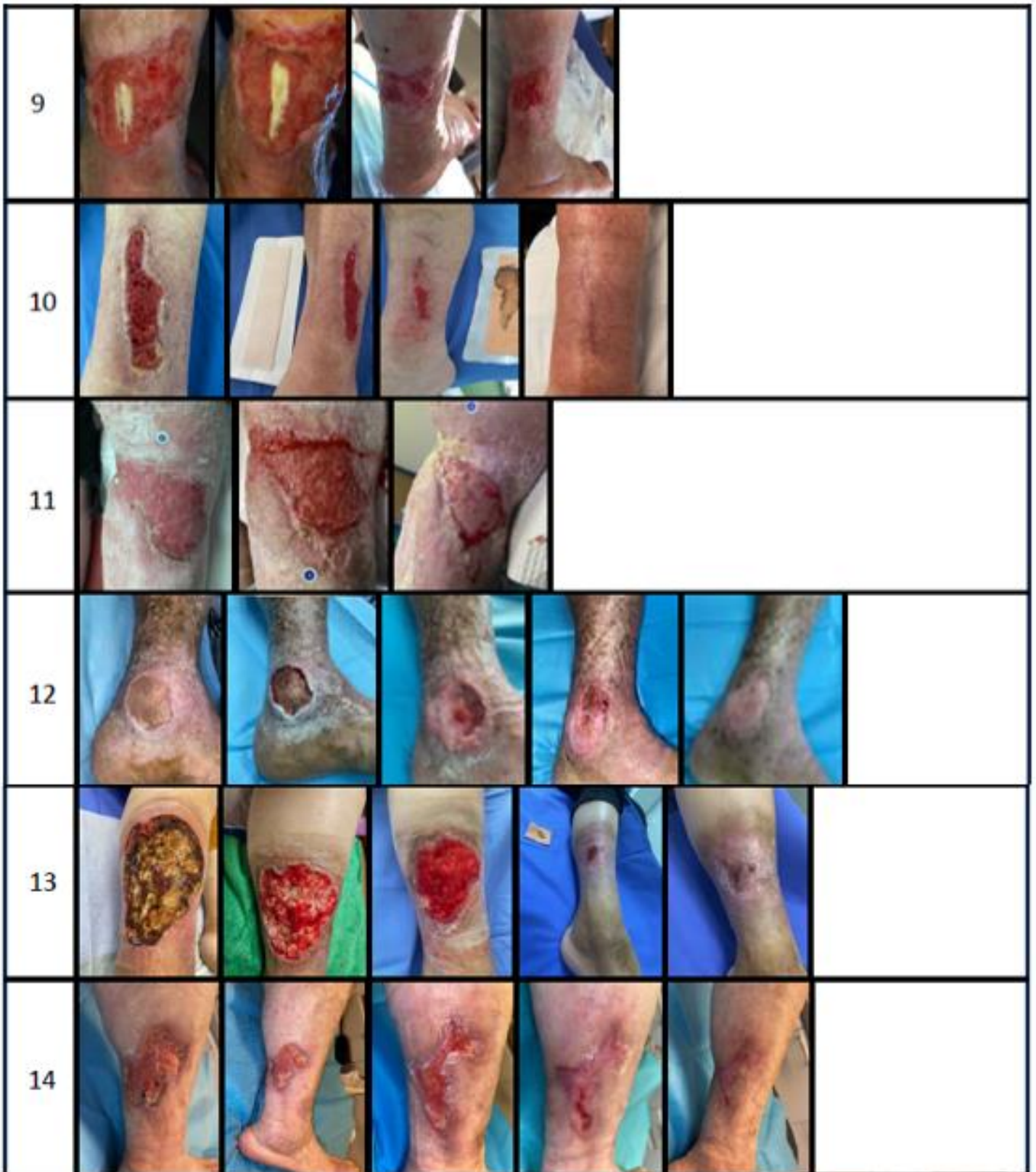
20	Chronic venous insufficiency, lipodermatosclerosis, dermatitis, post-thrombotic syndrome	72	F	3	Iodine dressings, Gauze	Yes	Scar avascular wound bed
21	Chronic venous insufficiency, cognitive impairment, obesity, dermatitis, lipodermatosclerosis	56	M	2.5	Iodine dressings	Yes	-
22	Chronic venous insufficiency, spinal stenosis, carpal tunnel syndrome	61	M	2	Iodine dressings, Aguacel Ag, Acticoat	Yes	-
23	Chronic venous insufficiency, carpal tunnel syndrome	61	F	2	Aguacel Ag	Yes	-
24	Chronic venous insufficiency, type 2 diabetes mellitus, hypertension	75	M	1.5	Iodine dressings, Acticoat	Yes	-
25	Chronic venous insufficiency, type 2 diabetes mellitus, chronic renal failure	83	M	1.5	Osmotic autolytic debridement	Yes	-

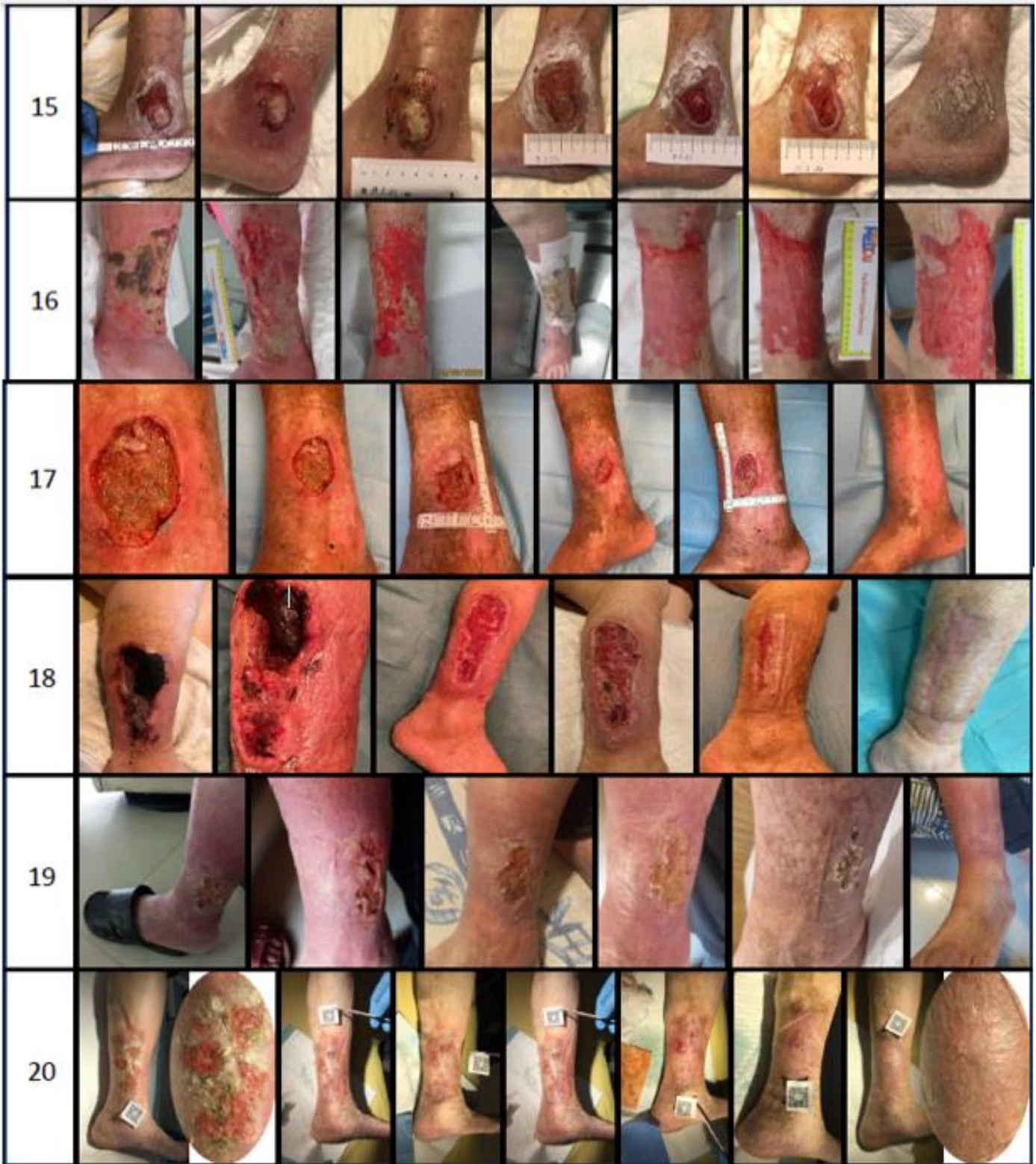Table 1: General patient characteristics at the beginning of treatment with the Copper Dressings and previous dressings used.

At the start of Copper Dressing treatment, all patients had good clear pulse palpation of the foot. A few of the patients presented with exposed bone or Achilles tendon, and all had signs of infection (Table 1). In all of the patients the Copper Dressings treatment was combined with compression therapy. Treatment with copper dressings lasted an average of 9.6 ± 5.97 weeks (Table 2), after which 20 of the 25 wounds (80%) completely healed (Figure 2). Of those 20 completely healed VLU, 16 (80%) were completely epithelialized within the first 12 weeks of treatment, the

remaining 4 clinical cases (20%) completely epithelialized within 14.6, 15, 17 and 32 weeks (clinical cases No. 3, 7, 6 and 8, respectively) of treatment. The mean RESVECH 2.0 score \pm standard deviation (SD) improved significantly, from 19.52 ± 5.38 at baseline to 2.44 ± 4.92 following treatment (Table 2) (Wilcoxon signed-rank test, $p < 0.001$). The mean \pm SD score change (Δ score: beginning – end) per week treatment was 2.18 ± 1.20 .







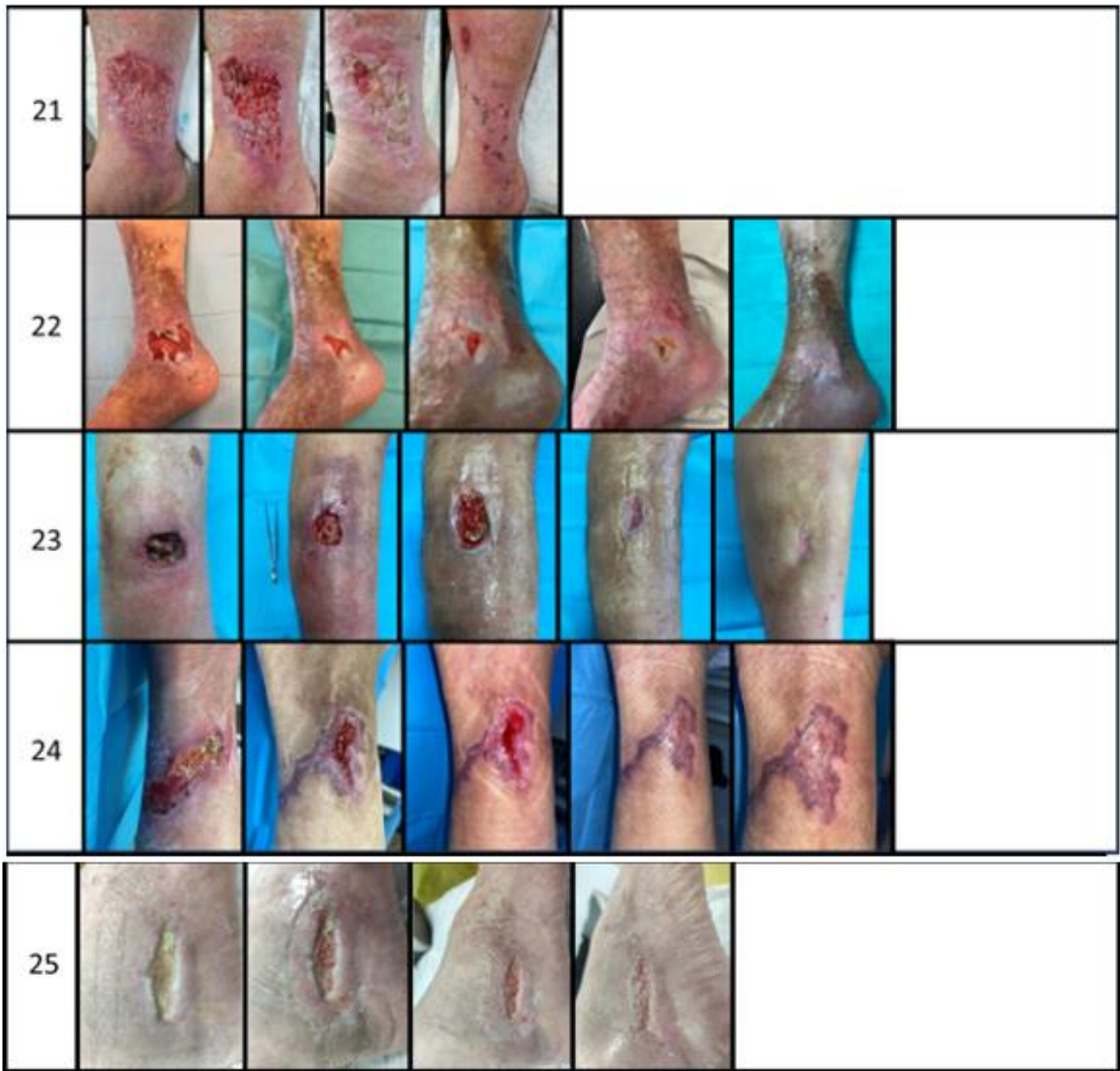


Figure 2: Healing of Venous Leg Ulcers (VLUs) with Copper Dressings.

This figure presents the healing progression of VLUs in all 25 patients included in the study. The cases are arranged in order, from the longest-standing to the most recently developed VLUs. For each case, the left

image shows the wound at the start of treatment with copper dressings, while the right image shows the wound at closure or at the final documented stage. Patient numbers correspond to those listed in Table 1.

Patient	Time of Treatment (Weeks)	RESVECH 2.0 SCORE	
		Pre-treatment	Post-treatment
1	6.4	20	12
2	6	23	12
3	14.6	12	0
4	12	18	0
5	4	7	0
6	17	23	0
7	15	21	0
8	32	28	0
9	8.6	26	14
10	4	13	0

11	6	21	13
12	10	24	0
13	12	12	0
14	8	19	0
15	12	28	0
16	6.4	24	10
17	9	20	0
18	10	26	0
19	12	14	0
20	6.8	12	0
21	4	23	0
22	5	21	0
23	5	18	0
24	4	18	0
25	10	17	0
Mean ± SD	9.6 ± 5.87	19.52 ± 5.38	2.44 ± 4.92

Table 2: Copper Dressings Treatment.

Discussion

In the present study, we report multiple cases of stagnant, hard-to-heal VLUs in patients with diverse underlying etiologies that responded favorably to treatment with Copper Dressings. Previous studies have demonstrated the capacity of Copper Dressings to stimulate wound healing through the continuum of care [19,20,22,24-26,31]; however, nearly all of those investigations focused on diabetic wounds. To date, only a single case reported the successful use of Copper Dressings in treating a heavily infected venous ulcer [19].

The cases presented here involve VLUs that did not heal despite prior standard-of-care wound management strategies—including compression therapy, NPWT and various dressing types (including antimicrobial dressings) - some for even several years. The patients studied represent a wide array of different chronic comorbidities. Remarkably, upon initiating treatment with Copper Dressings, all wounds demonstrated rapid and notable improvement in wound bed quality. This included wounds that did not respond well to antimicrobial dressings (e.g. silver containing dressings), similarly to a previous publication showing enhanced wound healing by copper dressings of wounds that responded poorly to silver dressings [23].

These improvements included enhanced autolytic debridement, emergence of granulation tissue, epithelialization, reduction in edema, and measurable wound size reduction. Importantly, no maceration of the wound margins was observed. 80 percent of the wounds closed within 12 weeks of treatment, in contrast to 93% of VLUs that heal in 12 months [17].

This case series encompasses patients from eight different countries and nine distinct wound clinics or hospitals, managed by various wound care specialists. These findings strongly suggest that the therapeutic efficacy of Copper Dressings in managing VLUs is consistent across diverse clinical settings and independent of individual practitioners' expertise.

The copper oxide microparticles impregnated in the Copper Dressings serve as a reservoir of copper ions that are continuously liberated to the wound bed at ppm levels [19-20]. These copper ions kill pathogens present in the wound [18], primarily by plasma membrane permeabilization, membrane lipid peroxidation, and inhibition of microbial proteins assembly and activity [32]. The several parallel non-specific multisite copper antimicrobial kill mechanisms make the development of resistant microorganisms to copper extremely difficult [33]. The copper ions can also kill bacteria protected by biofilm [21].

It has been demonstrated that applying copper dressings to non-infected wounds in genetically engineered diabetic mice stimulates the secretion of key wound-healing factors through upregulation of the oxygen-sensing protein hypoxia-inducible factor-1 (HIF-1) [34]. Under hypoxic conditions, HIF-1 activates transcription of genes that promote

angiogenesis, fibroblast proliferation, and keratinocyte migration, thereby accelerating tissue repair [35]. In chronic wounds such as diabetic ulcers, however, HIF-1 activity is impaired and fails to respond adequately to hypoxia [36]. Notably, copper ions not only provide broad-spectrum antimicrobial protection [37], but also directly enhance wound-healing processes by upregulating HIF-1 [34]. Today, the essential role of copper across all stages of wound healing is well established [38]. Copper ions also stimulate the secretion of vascular endothelial growth factor (VEGF), collagens and elastin by the dermal fibroblasts, promoting angiogenesis and extracellular matrix (ECM) formation during the proliferation and remodeling phases [39]. Copper is essential for the activity of Lysyl oxidase (LOX) for the ECM stabilization during the proliferation phase [39-43]. Copper is a cofactor of matrix metalloproteinases (MMPs) [44], superoxide dismutase [39] and tyrosinase [45], enzymes involved in debridement and skin remodeling, protection from oxidative stress, and for melanin production and skin pigmentation, respectively. It is thus contemplated that the stimulation of some or all of the above-mentioned factors by copper results in the stimulation of wound healing processes even in stagnated chronic wounds, including VLUs. By contrast, silver ions have been shown to downregulate HIF-1 [46], which may help explain growing evidence that silver dressings can impede wound-healing processes [47-49].

One of the bases of VLU management is compression therapy [50]. In the present case series, the Copper Dressings were used in combination with compression therapy. The level of compression (from light to strong) and the type of compression (stockings, single and multi-layer compression bandaging) depend on the level of edema, patient's mobility (resting and walking pressure), configuration of the lower extremity, patient's tolerance to the type and level of compression [51]. Based on our experience, Copper Dressings are suitable for use under various types of compression therapy. Due to its soft material components and sizing it can be easily applied and configured around the circumference of the lower leg under compression therapy; in consequence of its absorbent properties and minimal height, it prevents horizontal exudate leakage (maceration) and skin damage over the boarder of the dressing under compression therapy; and can be easily removed when changing the dressing.

The study is a retrospective, non-randomized case series, which inherently lacks a control group or comparator treatment arm. The study presents only a relatively small number of patients, which limits statistical power. Future studies should directly compare copper dressings against standard of care or other interventions and control for potential confounders, such as compression regimen differences, mobility and dressing change frequency across patients.

Conclusions

This case series provides clear evidence for the beneficial role of copper oxide-impregnated dressings in the healing of hard-to-heal venous leg

ulcers. The findings align with previously established data highlighting copper's critical involvement in key physiological wound healing processes, including angiogenesis, extracellular matrix remodeling, and antimicrobial protection. The consistent clinical improvements observed across a diverse patient population further support the use of Copper Dressings as an effective management strategy for venous leg ulcers - complementing earlier studies that demonstrated their efficacy in the treatment of diabetic wounds. These results underscore the potential of Copper Dressings to serve as a versatile and impactful tool in hard-to-heal wound care.

Abbreviations

The following abbreviations are used in this manuscript:

NPWT	Negative Pressure Wound Therapy
VLU	Venous leg ulcers
CT	Compression Therapy
ECM	Extracellular matrix
HIF-1	Hypoxia-inducible factor-1

References

- Margolis David J, Bilker Warren, Santanna Jill, Baumgarten Mona, (2002). Venous leg ulcer: incidence and prevalence in the elderly. *J Am Acad Dermatol*; 46(3):381-386.
- Nelzén Olle, (2008). Prevalence of venous leg ulcer: The importance of the data collection method. *Phlebology*; 15(4):143-150.
- Xie Ting, Ye Junna, Rerkasem Kittipan, Mani Rajgopal, (2018). The venous ulcer continues to be a clinical challenge: an update. *Burns Trauma*; 6(18).
- Spear Marcia, (2012), Venous ulcers--an evidence-based update. *Plast Surg Nurs*; 32(4):185-188.
- Vowden Kathryn R, Vowden Peter, (2006). Preventing venous ulcer recurrence: a review. *Int Wound J*; 3(1):11-21.
- Aleksandrowicz Hubert, Owczarczyk-Saczonek Agnieszka, Placek Waldemar, (2021). Venous Leg Ulcers: Advanced Therapies and New Technologies. *Biomedicines*; 9(11).
- Shaydakov Maxim E, Ting Windsor, Sadek Mikel, Aziz Faisal, Diaz Jose A. et al. (2022). Review of the current evidence for topical treatment for venous leg ulcers. *J Vasc Surg Venous Lymphat Disord.*; 10(1):241-247 e15.
- Bingyang He, Junfang Shi, Lingyan Li, Yuan Yuan Ma, Han Zhao. et al. (2024). Prevention strategies for the recurrence of venous leg ulcers: A scoping review. *Int Wound J*; 21(3):e14759.
- Leren Lena, Johansen Edda, Eide Hilde, Falk Ragnhild S, Juvet Lene K, et al. (2020). Pain in persons with chronic venous leg ulcers: A systematic review and meta-analysis. *Int Wound J*; 17(2):466-484.
- Millan Susan B, Gan Run, Townsend Petra E. (2019). Venous Ulcers: Diagnosis and Treatment. *Am Fam Physician*; 100(5):298-305.
- Mosti Giovanni, (2013). Wound care in venous ulcers. *Phlebology*; 28 Suppl 1(79-85).
- Kim Junglyun, Stechmiller Joyce, Weaver Michael, James Garth, Stewart Philip S. (2024). Associations Among Wound-Related Factors Including Biofilm, Wound-Related Symptoms and Systemic Inflammation in Older Adults with Chronic Venous Leg Ulcers. *Adv Wound Care (New Rochelle)*; 13(10):518-527.
- Stewart Philip S, Kim Junglyun, James Garth, Yi Fan, Stechmiller Joyce. et al. (2024). Association of biofilm and microbial metrics with healing rate in older adults with chronic venous leg ulcers. *Wound Repair Regen*; 32(6):858-871.
- Snyder Robert J, Cardinal Matthew, Dauphinee Damien M, Stavosky James; (2010). A post-hoc analysis of reduction in diabetic foot ulcer size at 4 weeks as a predictor of healing by 12 weeks. *Ostomy Wound Manage*; 56(3):44-50.
- Coerper Stephan, Beckert Stefan, Kuper Markus A, Jekov Martin, Konigsrainer Alfred; (2009). Fifty percent area reduction after 4 weeks of treatment is a reliable indicator for healing--analysis of a single-center cohort of 704 diabetic patients. *J Diabetes Complications*; 23(1):49-53.
- Cardinal Matthew, Eisenbud David E, Phillips Tania, Harding Keith; (2008). Early healing rates and wound area measurements are reliable predictors of later complete wound closure. *Wound Repair Regen*; 16(1):19-22.
- Harrison Margaret B, Graham Ian D.; Friedberg Elaine, Lorimer Karen, Vandervelde-Coke, Susan, (2001). Assessing the population with leg and foot ulcers. *Canadian Nurse*;97(2):18-23.
- Borkow Gadi, Roth Tohar, Kalinkovich Alexander, (2022). Wide spectrum potent antimicrobial efficacy of wound dressings impregnated with cuprous oxide microparticles. *Microbiol. Res.*; 13(3):366-376.
- Melamed Eyal, Kiambi Patrick, Okoth Dancan, Honigber Irena, Tamir Eran, Borkow Gadi. (2021). Healing of Chronic Wounds by Copper Oxide-Impregnated Wound Dressings-Case Series. *Medicina (Kaunas)*; 57(3):296.
- Melamed Eyal, Borkow Gadi, (2023). Continuum of care in hard-to-heal wounds by copper dressings: a case series. *J Wound Care*; 32(12):788-796.
- Roth Tohar, Zelinger Einat, Kossovsky Tally, Borkow Gadi, (2024). Scanning Electron Microscopy Analysis of Biofilm-Encased Bacteria Exposed to Cuprous Oxide-Impregnated Wound Dressings. *Microbiol. Res.*; 15(4):2358-2368.
- Borkow Gadi, Melamed Eyal, (2025). The Journey of Copper-Impregnated Dressings in Wound Healing: From a Medical Hypothesis to Clinical Practice. *Biomedicines*; 13(3).
- Gorel Oxana, Hamuda Mozna, Feldman Ilana, Kucyn-Gabovich Irit, (2024). Enhanced healing of wounds that responded poorly to silver dressing by copper wound dressings: Prospective single arm treatment study. *Health Sci. Rep.*; 7(e1816).
- Weitman Cernica C, Roth Tohar, Borkow Gadi, (2022). Copper dressings to the wound rescue after everything else failed: case report. *Arch Clin Med Case Rep.*; 6(3):466-473.
- Melamed Eyal, Rovitsky Alexei, Roth Tohar, Assa Lior, Borkow Gadi, (2021). Stimulation of Healing of Non-Infected Stagnated Diabetic Wounds by Copper Oxide-Impregnated Wound Dressings. *Medicina (Kaunas)*; 57(10):1129.
- Melamed Eyal, Rovitsky Alexei, Roth Tohar, Borkow Gadi, (2022). Anterior ankle full thickness skin necrosis treated with copper oxide dressings without debridement and skin graft - a case report. *Arch Clin Med Case Rep.*; 6(501-510).

27. Philips Neena, Samuel Philips, Parakandi Harit, Gopal Sesha, Siomyk Halyna. et al. (2012). Beneficial regulation of fibrillar collagens, heat shock protein-47, elastin fiber components, transforming growth factor-beta1, vascular endothelial growth factor and oxidative stress effects by copper in dermal fibroblasts. *Connect Tissue Res.*; 53(5):373-378.
28. Sen Chandan K, Khanna Savita, Venojarvi Mika, Trikha Prashant, Ellison Christopher E. et al. (2002). Copper-induced vascular endothelial growth factor expression and wound healing. *Am J Physiol Heart Circ Physiol.*; 282(5):H1821-H1827.
29. Gerard Catherine, Bordeleau Louis-Jean, Barralet Jake, Doillon Charles J, (2010). The stimulation of angiogenesis and collagen deposition by copper. *Biomaterials*; 31(5):824-831.
30. Ogen-Shtern Navit, Chumin Katerina, Cohen Guy, Borkow Gadi, (2020). Increased pro-collagen 1, elastin, and TGF-beta1 expression by copper ions in an ex-vivo human skin model. *J Cosmet Dermatol.*; 19(6):1522-1527.
31. Tsai Cheng-Yu, Finley Cameron J, Ali Sameh S, Patel Hemal H, Howell Stephen B, (2012). Copper influx transporter 1 is required for FGF, PDGF and EGF-induced MAPK signaling. *Biochem Pharmacol.*; 84(8):1007-1013.
32. Philips Neena, Hwang Hyeondo, Chauhan Sagar, Leonardi Donna, Gonzalez Salvador, (2010). Stimulation of cell proliferation and expression of matrixmetalloproteinase-1 and interleukin-8 genes in dermal fibroblasts by copper. *Connect Tissue Res*; 51(3):224-229.
33. Olivares Concepcion, Solano Francisco, (2009). New insights into the active site structure and catalytic mechanism of tyrosinase and its related proteins. *Pigment Cell Melanoma Res*; 22(6):750-760.
34. Yang Tieshan, Yao Qian, Cao Fei, Liu Qianqian, Liu Binlei, Wang Xiu-Hong, (2016). Silver nanoparticles inhibit the function of hypoxia-inducible factor-1 and target genes: insight into the cytotoxicity and antiangiogenesis. *Int J Nanomedicine*; 11(6679-6692).
35. Nagoba Basavraj S, Suryawanshi Namdev M, Selkar Sohan P, (2013). Cytotoxicity of silver dressings-time to rethink and react. *Int Wound J.*; 10(5):616.
36. Nešporová Kristina, Pavlík Vojtěch, Šafránková Barbora, Vágnerová Hana, Odrážka Pavel, Žídek Ondřej, et al. (2020). Effects of wound dressings containing silver on skin and immune cells. *Sci Rep.*; 10(1):15216.
37. Zou Shi-Bo, Yoon Won-Young, Han Seung-Kyu, Jeong Seong-Ho, Cui Zheng-Jun. et al. (2013). Cytotoxicity of silver dressings on diabetic fibroblasts. *Int Wound J.*; 10(3):306-12.
38. Tedeschi R, (2025). Compression therapy: revolutionizing venous ulcer care with precision and innovation. *Veins Lymphatics*; 14.
39. Haesler E. (2019). Evidence summary: Venous leg ulcers – multi-layer compression bandaging. *Wound Pract. Res.*; 27(1):49-51.



This work is licensed under Creative Commons Attribution 4.0 License

To Submit Your Article Click Here:

Submit Manuscript

DOI: [10.31579/2690-4861/986](https://doi.org/10.31579/2690-4861/986)

Ready to submit your research? Choose Auctores and benefit from:

- fast, convenient online submission
- rigorous peer review by experienced research in your field
- rapid publication on acceptance
- authors retain copyrights
- unique DOI for all articles
- immediate, unrestricted online access

At Auctores, research is always in progress.

Learn more <https://auctoresonline.org/journals/international-journal-of-clinical-case-reports-and-reviews>